

# Wrinkle Severity Rating Scale (WSRS) Training Slides

Edited by Dr. Doris Day

# Wrinkle Severity Rating Scale (WSRS)

Am J Clin Dermatology 2004; 5(1): 49-52 Doris J Day, Curt M Littler, Richard W. Swift, and Scott Gottlieb

## Purpose

- A validated 5 Point Reference scale with photographs that classifies deep facial wrinkles (Nasolabial Folds)
- WSRS enables valid and reproducible grading of Nasolabial Folds
- WSRS represents a clinically meaningful change in Nasolabial Fold severity from the adjacent grades

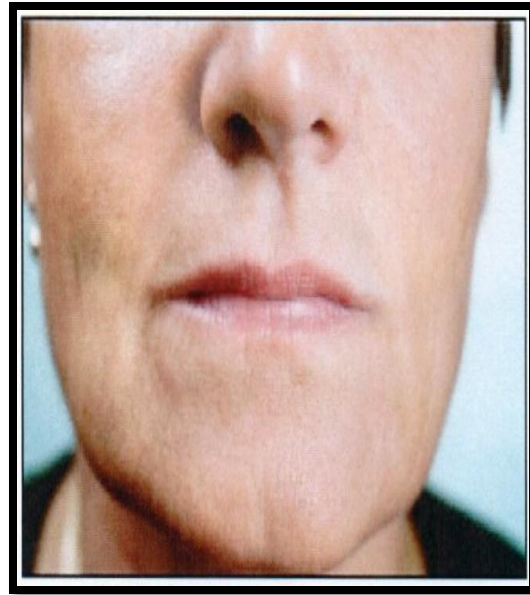
# Wrinkle Severity Rating Scale (WSRS)

## Wrinkle Severity Rating Scale (WSRS)

<u>Grade</u>	<u>Severity</u>
Grade 1	No visible NLF; continuous skin line
Grade 2	Shallow but visible NLF with a slight indentation
Grade 3	Moderate deep NLF; visible at normal appearance
Grade 4	Very long and deep NLF; prominent facial feature ;< 2mm visible fold if stretched
Grade 5	Extreme deep long NLF; 2-4mm V shaped fold if stretched

# Wrinkle Severity Rating Scale (WSRS)


- Grade 1 (absent)  
no visible nasolabial fold;  
continuous skin line



# Wrinkle Severity Rating Scale (WSRS)

- Grade 2 (Mild)


Shallow but visible nasolabial fold with a slight indentation; minor facial feature; implant is expected to produce a slight improvement in appearance



# Wrinkle Severity Rating Scale (WSRS)

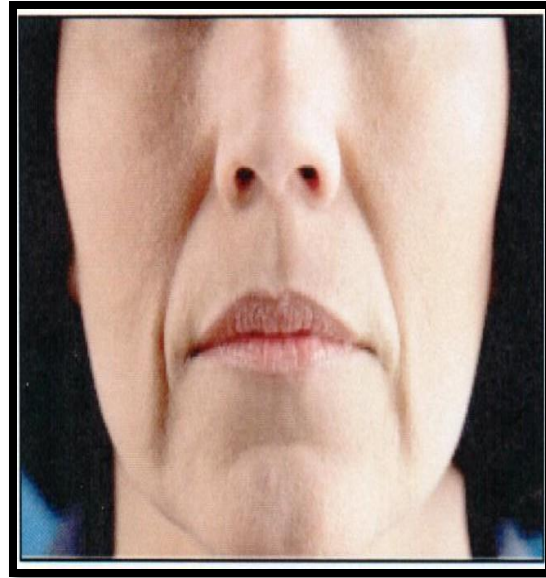
- Grade 3 (Moderate)

Moderately deep nasolabial folds; clear facial feature visible at normal appearance but not when stretched; excellent correction is expected with injectable implant



# Wrinkle Severity Rating Scale (WSRS)

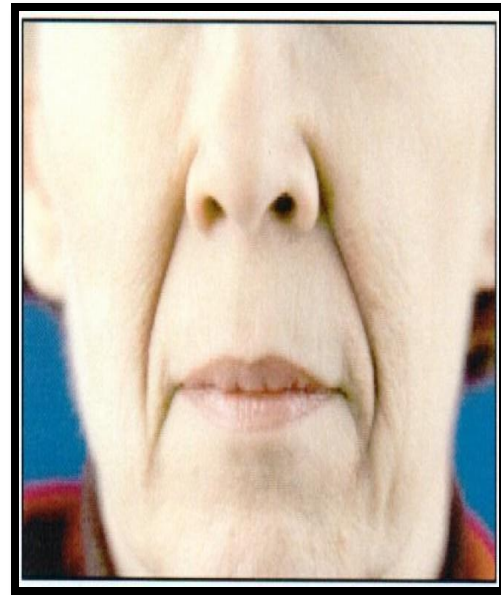
- Grade 4 (Severe)  
Very long and deep nasolabial folds; prominent facial feature; 2mm visible fold when stretched; significant improvement is expected with injectable implant



# Wrinkle Severity Rating Scale (WSRS)

- Grade 5 (Extreme)

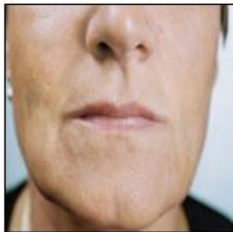Extremely deep and long nasolabial folds, detrimental to facial appearance; 2-4mm visible V-shaped fold when stretched; unlikely to have satisfactory correction with injectable implant alone



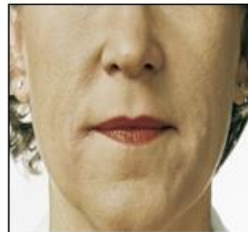

# Wrinkle Severity Rating Scale (WSRS)

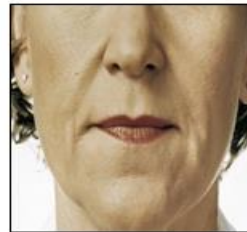## Wrinkle Severity Rating Scale<sup>1</sup>



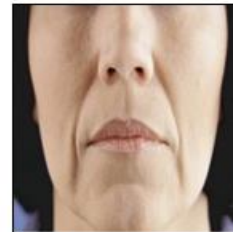**Grade 1**  
(Absent)  
No visible NLF  
Continuous skin line



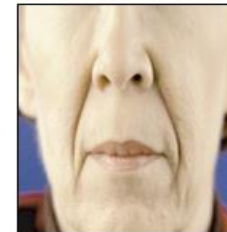**Grade 2**  
(Mild)  
Shallow but visible NLF  
with a slight indentation



**Grade 3**  
(Moderate)  
Moderate deep NLF  
Visible at normal appearance



**Grade 4**  
(Severe)  
Very long and deep NLF  
Prominent facial feature  
<2mm visible fold if stretched



**Grade 5**  
(Extreme)  
Extremely deep, long NLF  
2-4mm V shaped fold if stretched

<sup>1</sup>Day D, Littler C, Swift R, Gottlieb S "The Wrinkle Severity Rating Scale" A validation Study. American J Clin Derm 2004;5(1):49-52

# Wrinkle Severity Rating Scale (WSRS)

## Summary

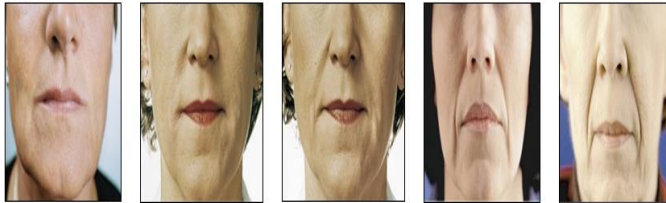The WSRS is a validated instrument for assessment of the nasolabial fold and has been approved by the FDA to use in a number of investigational device studies

# WSRS Patient Assessment

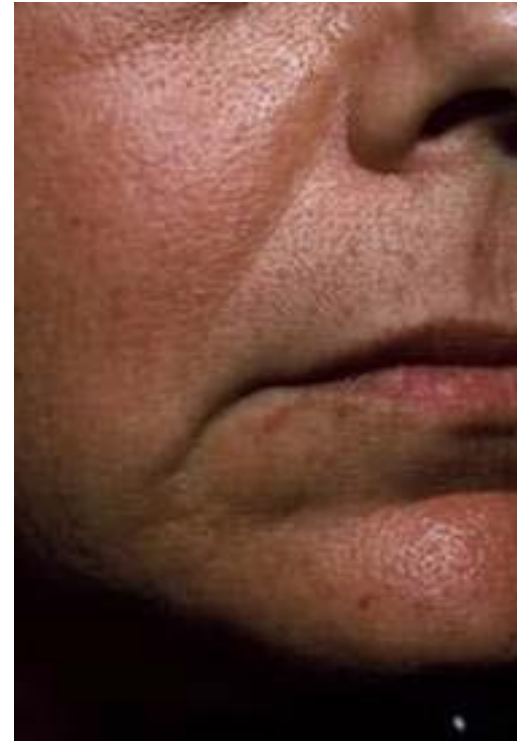- ✓ You will be asked to rate the following 10 photographic nasolabial fold images.
- ✓ Standardized definitions of the five grades are provided in each of the slides.
- ✓ Please fill out the test sheet provided, and fax the results to Premier Clinical Research. You must score 70% or greater otherwise a retest will be initiated.

# Patient 1

## Wrinkle Severity Rating Scale<sup>1</sup>



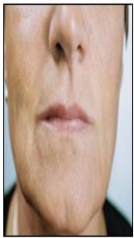<b>Grade 1</b> (Absent)	<b>Grade 2</b> (Mild)	<b>Grade 3</b> (Moderate)	<b>Grade 4</b> (Severe)	<b>Grade 5</b> (Extreme)
No visible NLF Continuous skin line	Shallow but visible NLF with a slight indentation	Moderate deep NLF Visible at normal appearance	Very long and deep NLF Prominent facial feature <2mm visible fold if stretched	Extremely deep, long NLF 2-4mm V shaped fold if stretched



<sup>1</sup>Day D, Littler C, Swift R, Gottlieb S "The Wrinkle Severity Rating Scale" A validation Study. American J Clin Derm 2004;5(1):49-52

# Patient 2

## Wrinkle Severity Rating Scale<sup>1</sup>



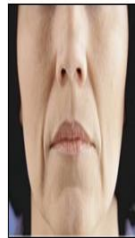
**Grade 1**  
(Absent)  
No visible NLF  
Continuous skin line



**Grade 2**  
(Mild)  
Shallow but visible NLF  
with a slight indentation



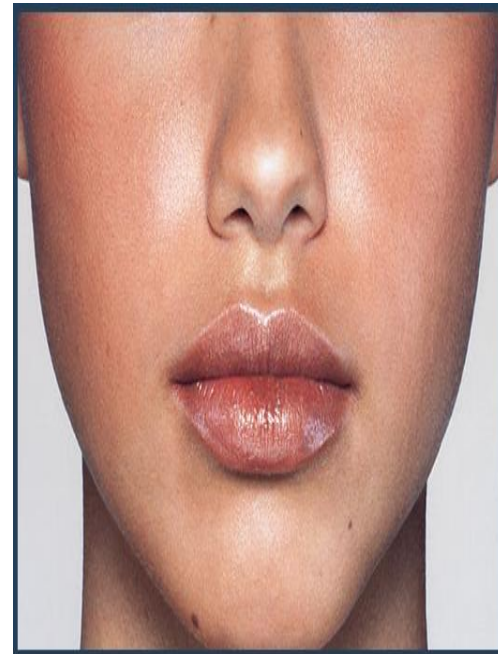
**Grade 3**  
(Moderate)  
Moderate deep NLF  
Visible at normal appearance



**Grade 4**  
(Severe)  
Very long and deep NLF  
Prominent facial feature  
<2mm visible fold if stretched



**Grade 5**  
(Extreme)  
Extremely deep, long NLF  
2-4mm V shaped fold if stretched



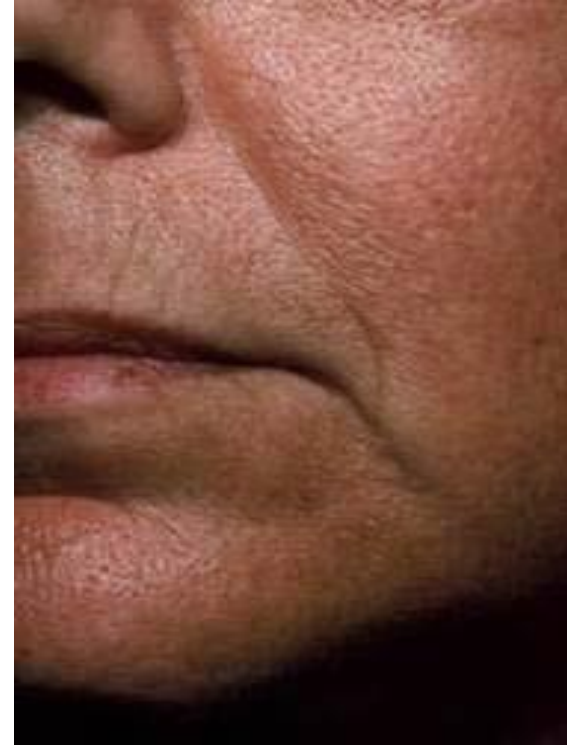<sup>1</sup>Day D, Littler C, Swift R, Gottlieb S "The Wrinkle Severity Rating Scale" A validation Study. American J Clin Derm 2004;5(1):49-52

# Patient 3

## Wrinkle Severity Rating Scale<sup>1</sup>



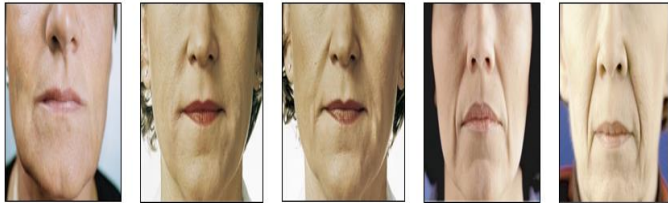<b>Grade 1</b> (Absent)	<b>Grade 2</b> (Mild)	<b>Grade 3</b> (Moderate)	<b>Grade 4</b> (Severe)	<b>Grade 5</b> (Extreme)
No visible NLF Continuous skin line	Shallow but visible NLF with a slight indentation	Moderate deep NLF Visible at normal appearance	Very long and deep NLF Prominent facial feature <2mm visible fold if stretched	Extremely deep, long NLF 2-4mm V shaped fold if stretched



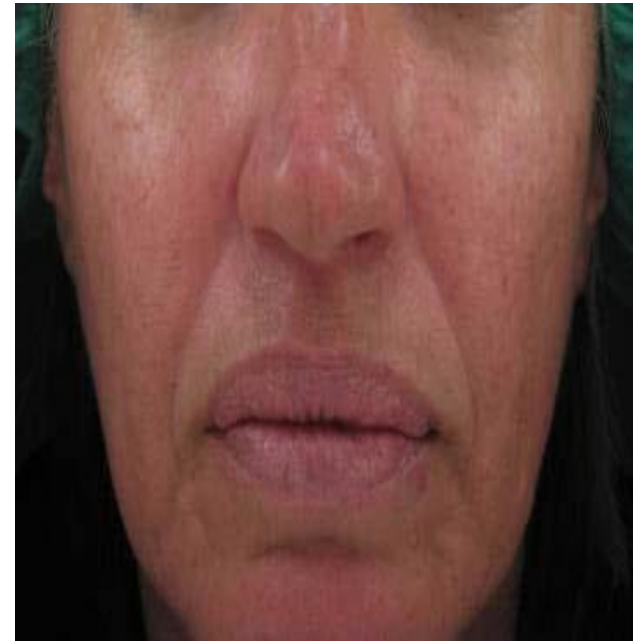<sup>1</sup>Day D, Littler C, Swift R, Gottlieb S "The Wrinkle Severity Rating Scale" A validation Study. American J Clin Derm 2004;5(1):49-52

# Patient 4

## Wrinkle Severity Rating Scale<sup>1</sup>



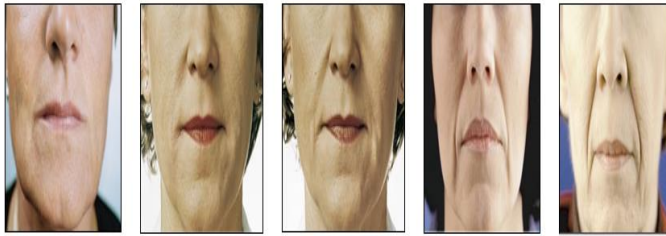<b>Grade 1</b> (Absent)	<b>Grade 2</b> (Mild)	<b>Grade 3</b> (Moderate)	<b>Grade 4</b> (Severe)	<b>Grade 5</b> (Extreme)
No visible NLF Continuous skin line	Shallow but visible NLF with a slight indentation	Moderate deep NLF Visible at normal appearance	Very long and deep NLF Prominent facial feature <2mm visible fold if stretched	Extremely deep, long NLF 2-4mm V shaped fold if stretched



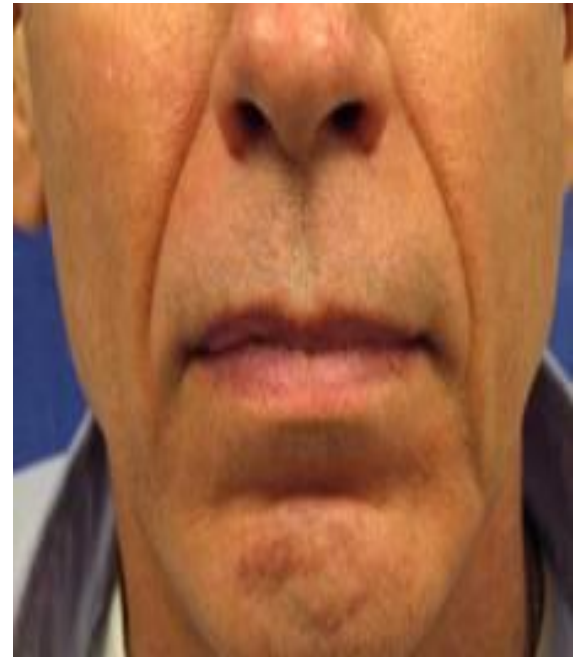<sup>1</sup>Day D, Littler C, Swift R, Gottlieb S "The Wrinkle Severity Rating Scale" A validation Study. American J Clin Derm 2004;5(1):49-52

# Patient 5

## Wrinkle Severity Rating Scale<sup>1</sup>



<b>Grade 1</b>	<b>Grade 2</b>	<b>Grade 3</b>	<b>Grade 4</b>	<b>Grade 5</b>
(Absent)	(Mild)	(Moderate)	(Severe)	(Extreme)
No visible NLF Continuous skin line	Shallow but visible NLF with a slight indentation	Moderate deep NLF Visible at normal appearance	Very long and deep NLF Prominent facial feature <2mm visible fold if stretched	Extremely deep, long NLF 2-4mm V shaped fold if stretched

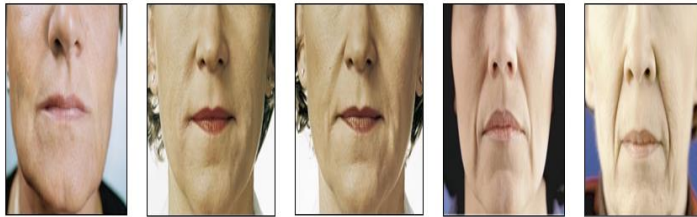

<sup>1</sup>Day D, Littler C, Swift R, Gortlieb S "The Wrinkle Severity Rating Scale" A validation Study. American J Clin Derm 2004;5(1):49-52

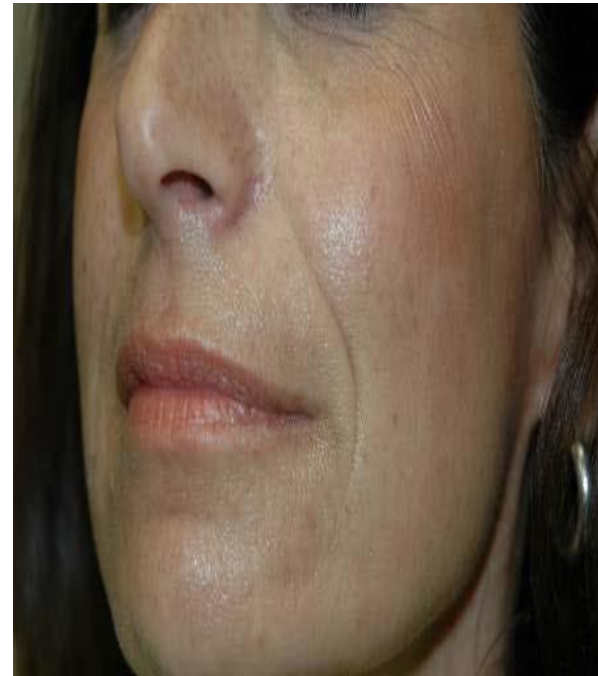

# Patient 6

## Wrinkle Severity Rating Scale<sup>1</sup>



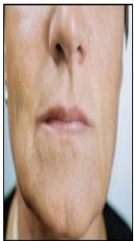<b>Grade 1</b> (Absent)	<b>Grade 2</b> (Mild)	<b>Grade 3</b> (Moderate)	<b>Grade 4</b> (Severe)	<b>Grade 5</b> (Extreme)
No visible NLF Continuous skin line	Shallow but visible NLF with a slight indentation	Moderate deep NLF Visible at normal appearance	Very long and deep NLF Prominent facial feature <2mm visible fold if stretched	Extremely deep, long NLF 2-4mm V shaped fold if stretched



<sup>1</sup>Day D, Littler C, Swift B, Gottlieb S "The Wrinkle Severity Rating Scale" A validation Study. American J Clin Derm 2004;5(1):49-52.

# Patient 7

## Wrinkle Severity Rating Scale<sup>1</sup>



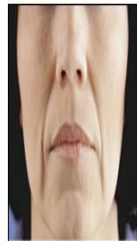**Grade 1**  
(Absent)  
No visible NLF  
Continuous skin line



**Grade 2**  
(Mild)  
Shallow but visible NLF  
with a slight indentation



**Grade 3**  
(Moderate)  
Moderate deep NLF  
Visible at normal appearance



**Grade 4**  
(Severe)  
Very long and deep NLF  
Prominent facial feature  
<2mm visible fold if stretched



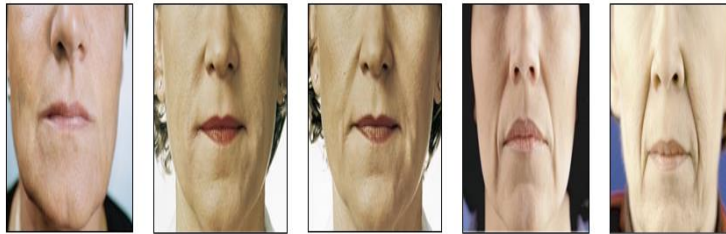**Grade 5**  
(Extreme)  
Extremely deep, long NLF  
2-4mm V shaped fold if stretched



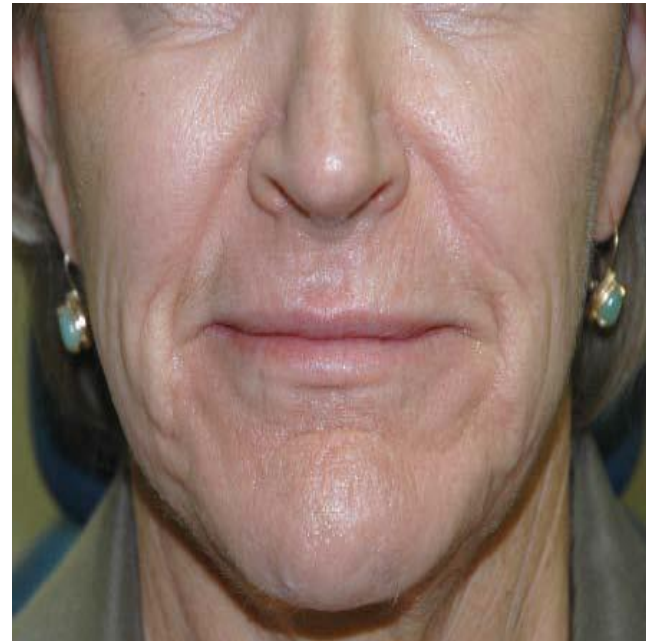
<sup>1</sup>Day D, Littler C, Swift R, Gottlieb S "The Wrinkle Severity Rating Scale" A Validation Study. American J Clin Derm 2004;5(1):49-52

# Patient 8

## Wrinkle Severity Rating Scale<sup>1</sup>



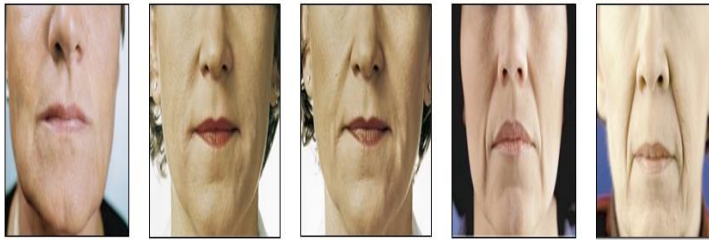
<b>Grade 1</b> (Absent)	<b>Grade 2</b> (Mild)	<b>Grade 3</b> (Moderate)	<b>Grade 4</b> (Severe)	<b>Grade 5</b> (Extreme)
No visible NLF Continuous skin line	Shallow but visible NLF with a slight indentation	Moderate deep NLF Visible at normal appearance	Very long and deep NLF Prominent facial feature <2mm visible fold if stretched	Extremely deep, long NLF 2-4mm V shaped fold if stretched



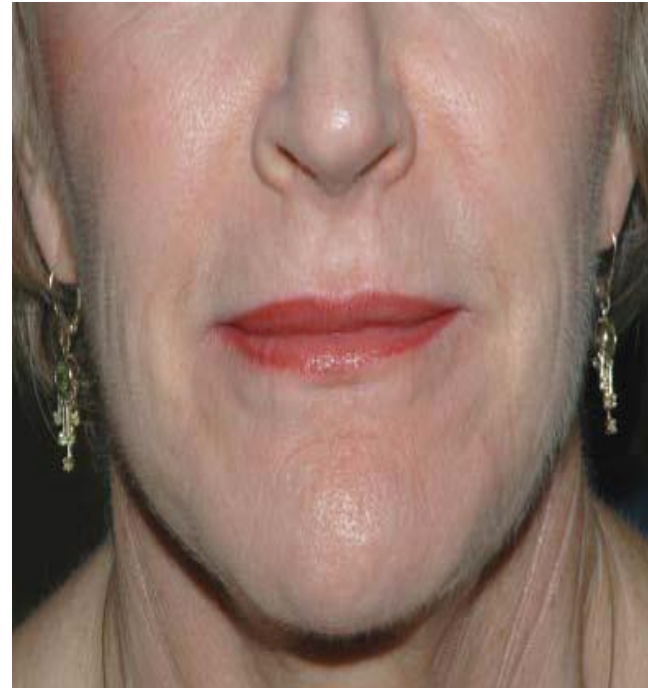<sup>1</sup>Day D, Littler C, Swift R, Gottlieb S "The Wrinkle Severity Rating Scale" A Validation Study. American J Clin Derm 2004;5(1):49-52

# Patient 9

## Wrinkle Severity Rating Scale<sup>1</sup>



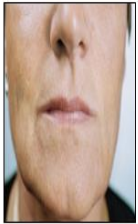<b>Grade 1</b>	<b>Grade 2</b>	<b>Grade 3</b>	<b>Grade 4</b>	<b>Grade 5</b>
(Absent)	(Mild)	(Moderate)	(Severe)	(Extreme)
No visible NLF Continuous skin line	Shallow but visible NLF with a slight indentation	Moderate deep NLF Visible at normal appearance	Very long and deep NLF Prominent facial feature	Extremely deep, long NLF 2-4mm V shaped fold if stretched <2mm visible fold if stretched



<sup>1</sup>Day D, Littler C, Swift R, Gottlieb S "The Wrinkle Severity Rating Scale" A validation Study, American J Clin Derm 2004;5(1):49-52

# Patient 10

## Wrinkle Severity Rating Scale<sup>1</sup>



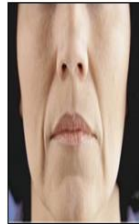**Grade 1**  
(Absent)  
No visible NLF  
Continuous skin line



**Grade 2**  
(Mild)  
Shallow but visible NLF  
with a slight indentation



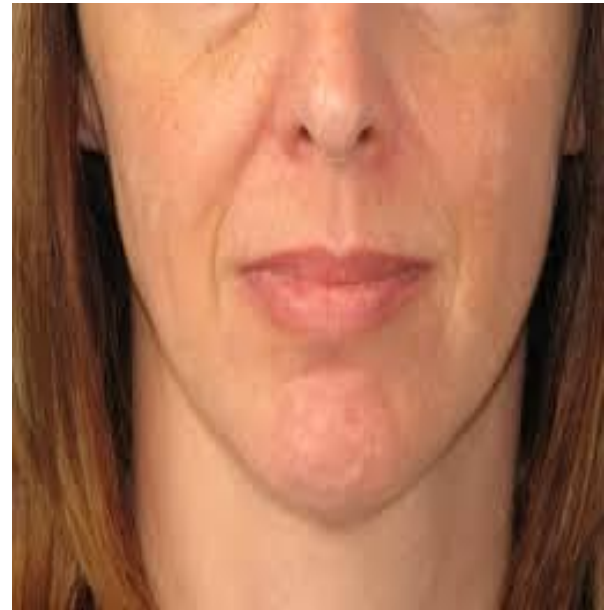**Grade 3**  
(Moderate)  
Moderate deep NLF  
Visible at normal appearance



**Grade 4**  
(Severe)  
Very long and deep NLF  
Prominent facial feature  
<2mm visible fold if stretched



**Grade 5**  
(Extreme)  
Extremely deep, long NLF  
2-4mm V shaped fold if stretched



<sup>1</sup>Day D, Littler C, Swift R, Gottlieb S "The Wrinkle Severity Rating Scale" A validation Study. American J Clin Derm 2004;5(1):49-52